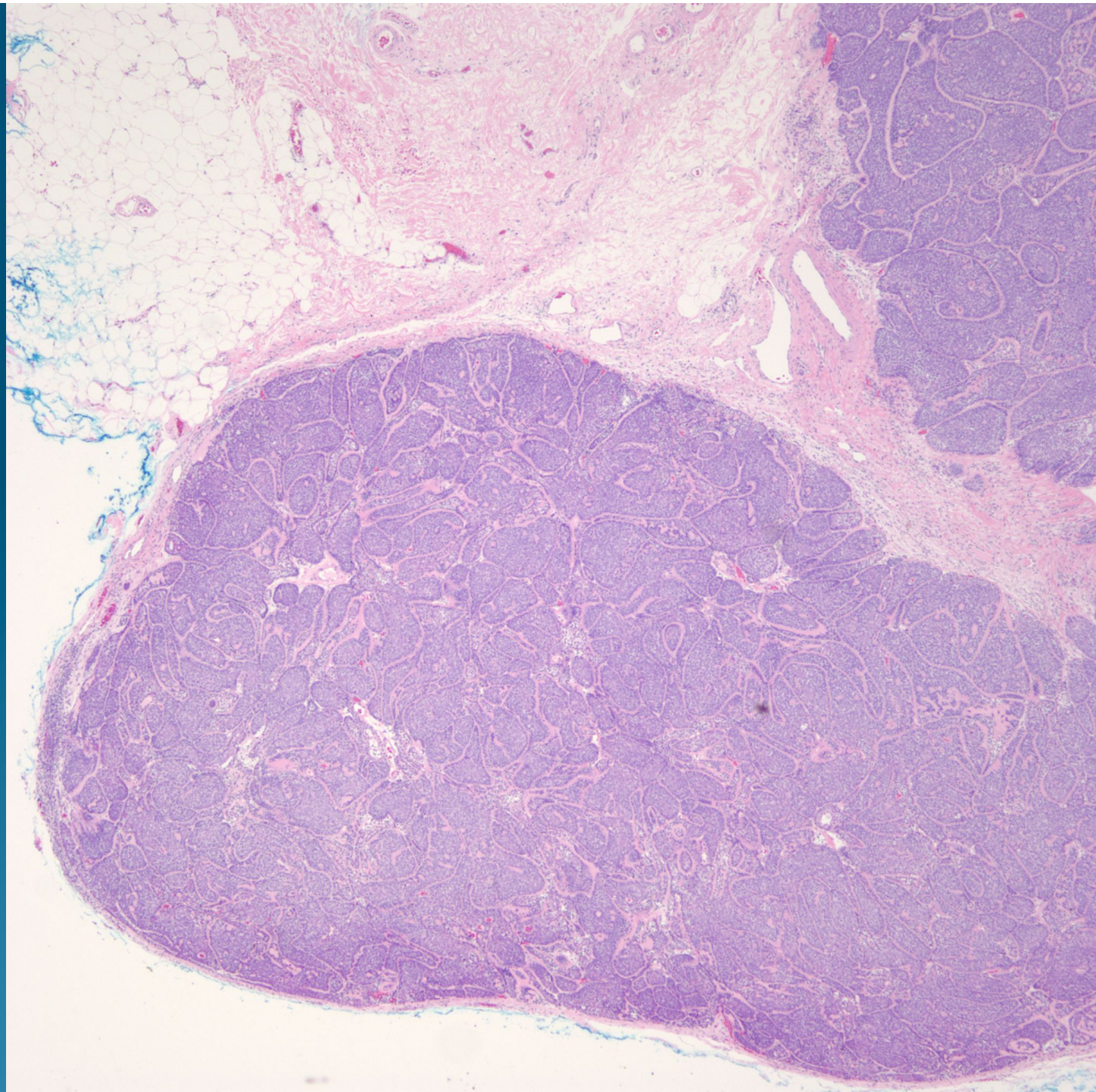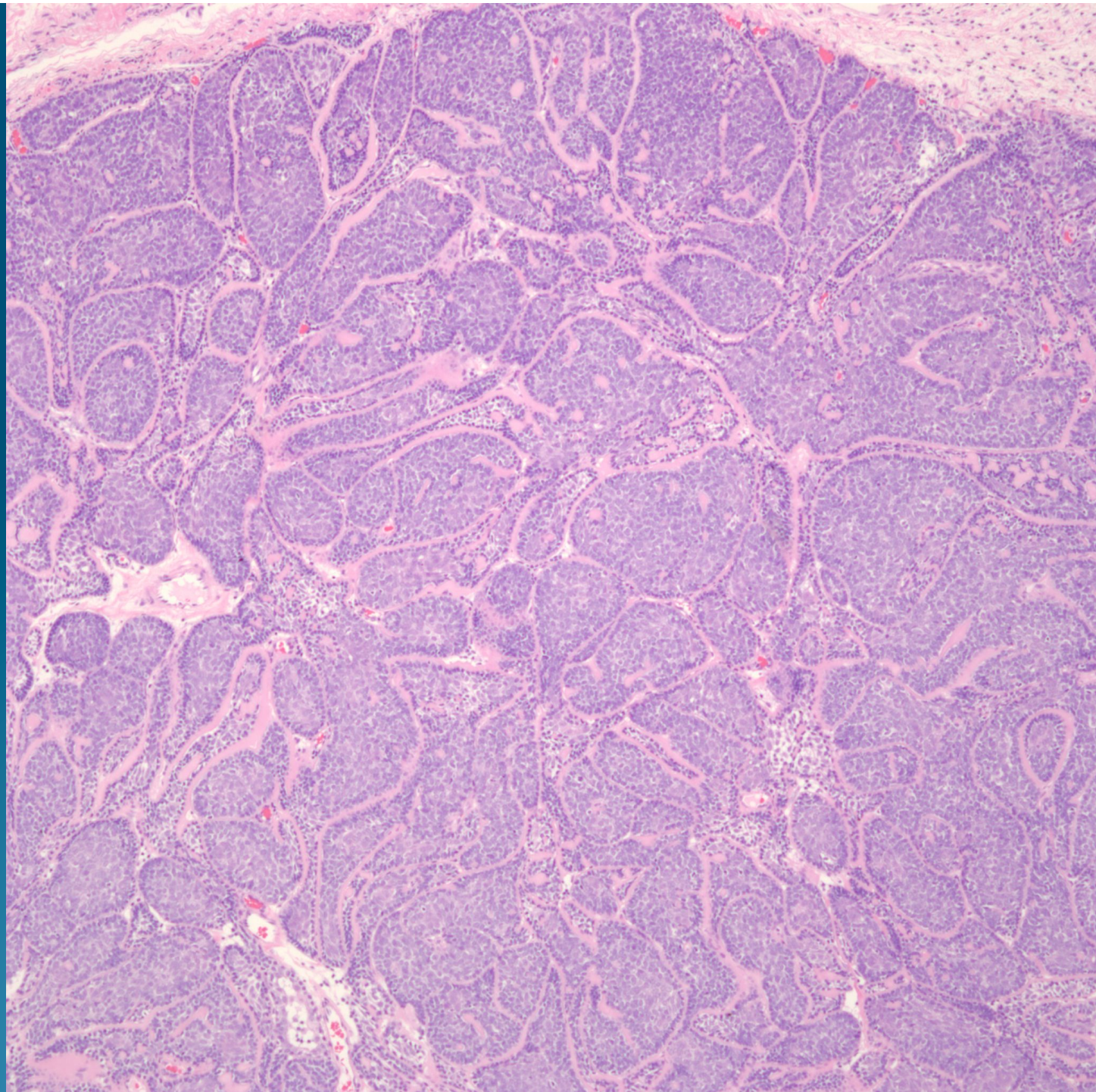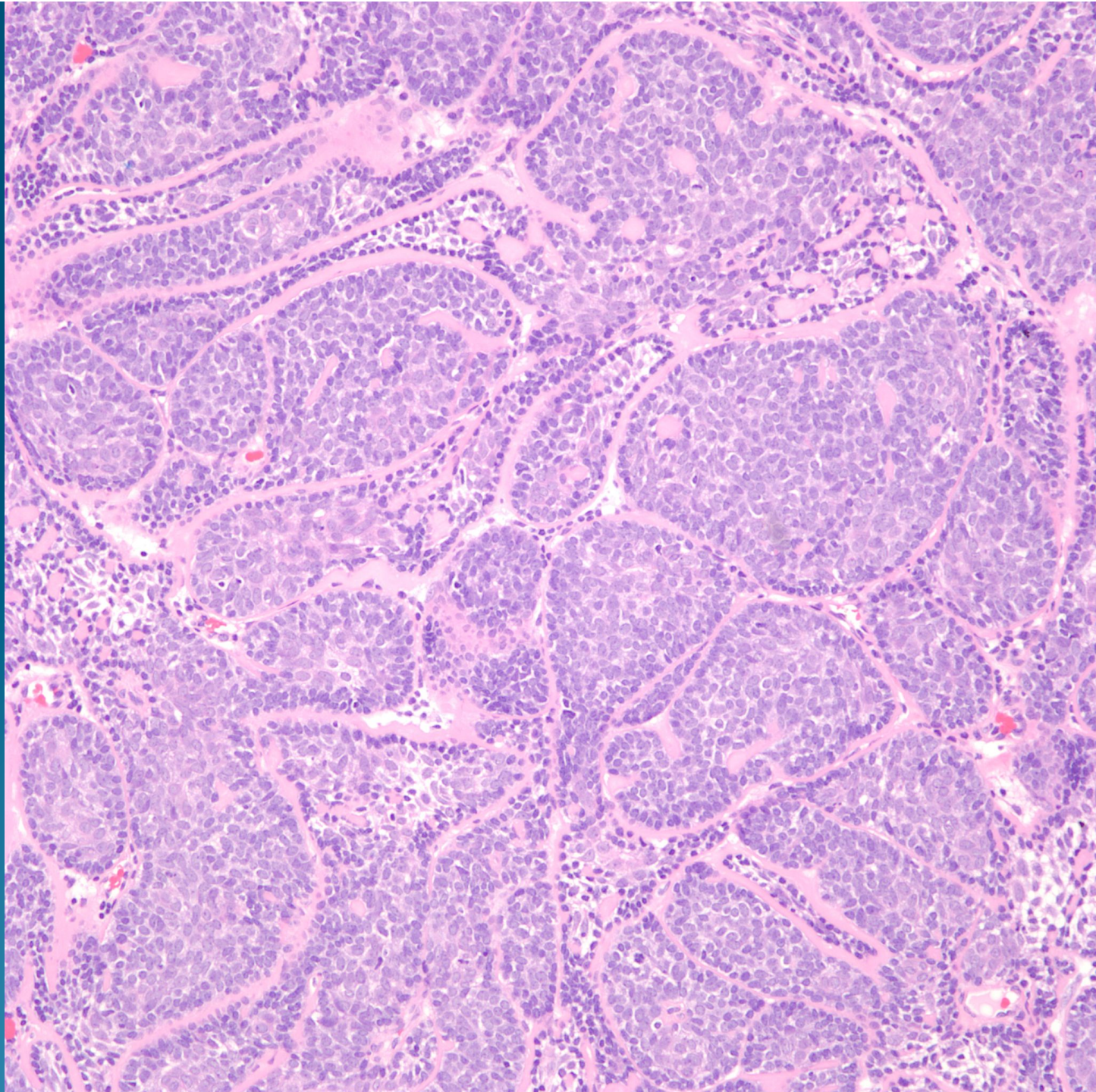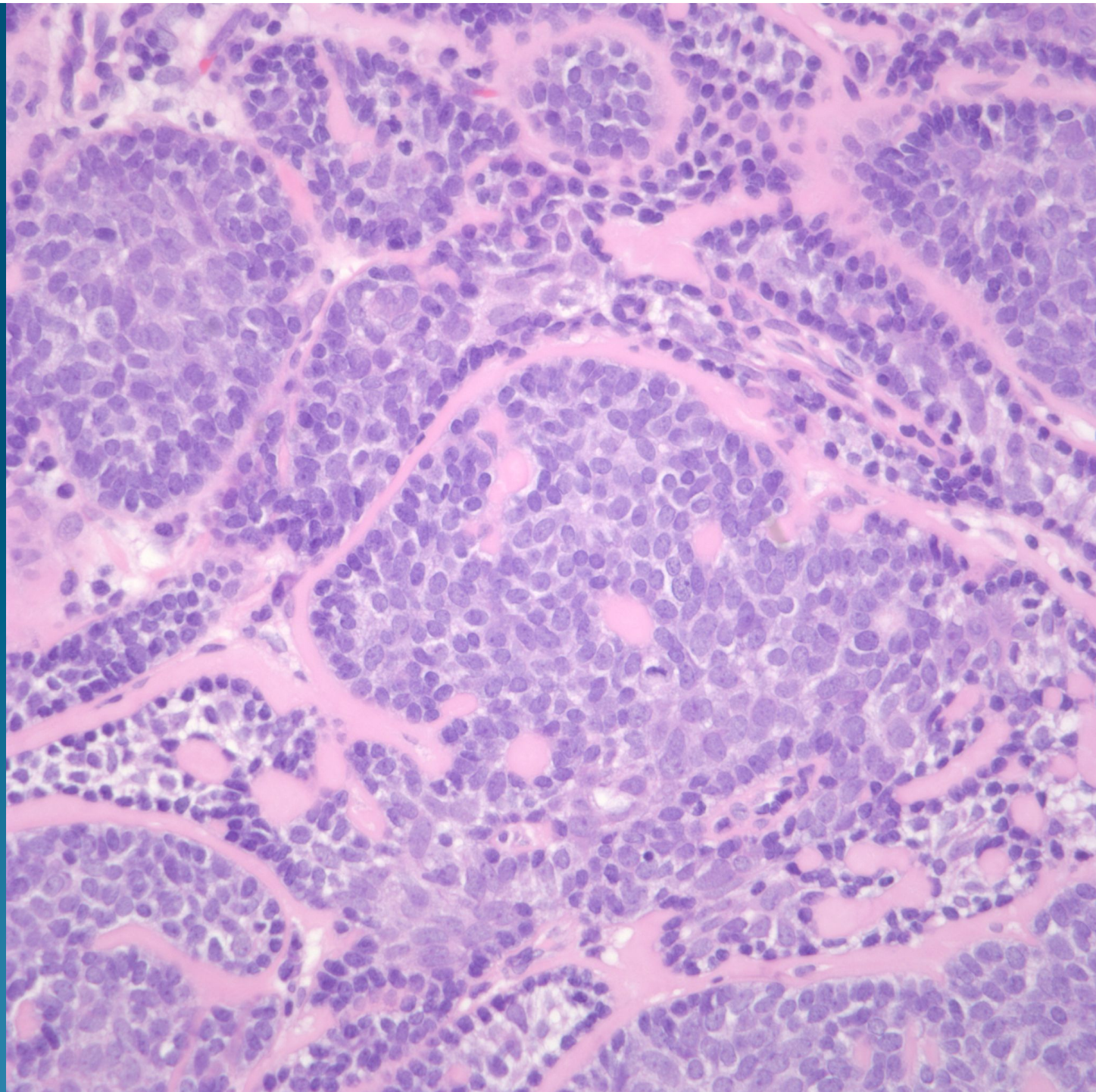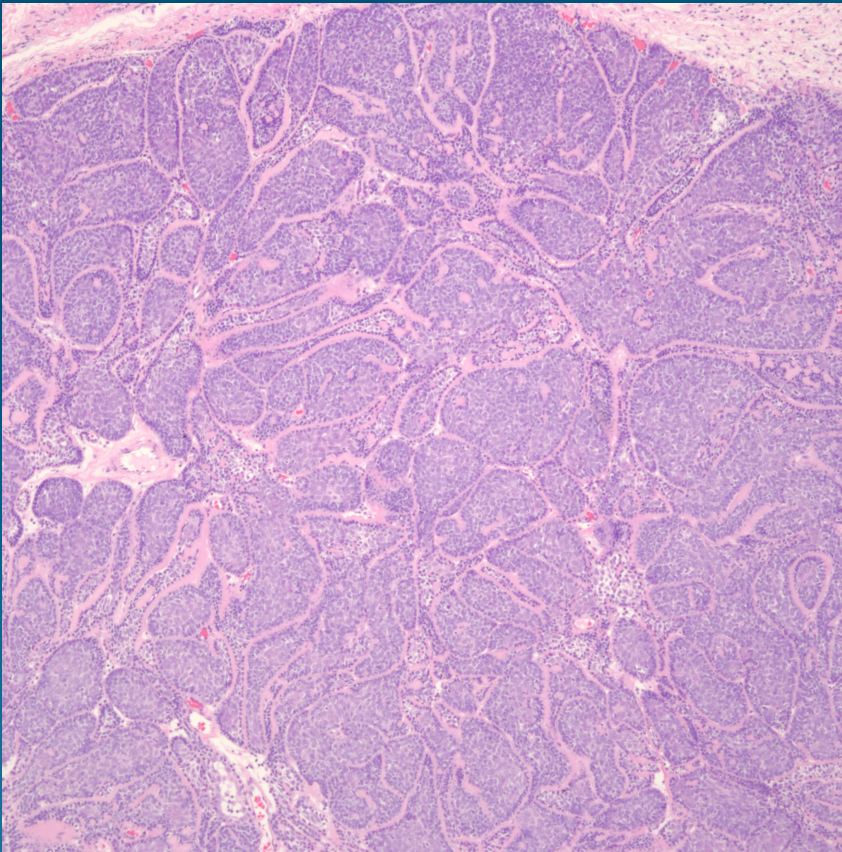


What is the best diagnosis?

- A. Cylindroma
- B. Basal cell carcinoma, nodular type
- C. Trichoepithelioma
- D. Glomus tumor
- E. Merkel cell carcinoma

Cylindroma

Pearls



- Circumscribed dermal nodules with no epidermal attachment
- Basaloid cells divided by hyalinized basement membrane imparting a “jigsaw puzzle-like” appearance